

Limited vs Extended Face-lift Techniques

Objective Analysis of Intraoperative Results

Jason A. Litner, MD, FRCSC; Peter A. Adamson, MD, FRCSC, FACS

Objective: To compare the intraoperative outcomes of superficial musculoaponeurotic system plication, imbrication, and deep-plane rhytidectomy techniques.

Methods: Thirty-two patients undergoing primary deep-plane rhytidectomy participated. Each hemiface in all patients was submitted sequentially to 3 progressively more extensive lifts, while other variables were standardized. Four major outcome measures were studied, including the extent of skin redundancy and the repositioning of soft tissues along the malar, mandibular, and cervical vectors of lift. The amount of skin excess was measured without tension from the free edge to a point over the intertragal incisure, along a plane overlying the jawline. Using a soft tissue caliper, repositioning was examined by measurement of preintervention and immediate postinter-

vention distances from dependent points to fixed anthropometric reference points.

Results: The mean skin excesses were 10.4, 12.8, and 19.4 mm for the plication, imbrication, and deep-plane lifts, respectively. The greatest absolute soft tissue repositioning was noted along the jawline, with the least in the midface. Analysis revealed significant differences from baseline and between lift types for each of the studied techniques in each of the variables tested.

Conclusion: These data support the use of the deep-plane rhytidectomy technique to achieve a superior intraoperative lift relative to comparator techniques.

Arch Facial Plast Surg. 2006;8:186-190

SEVERAL FACE-LIFT TECHNIQUES have been developed to address a widely perceived shortcoming of traditional face-lift approaches, namely, persistent midfacial ptosis. Some surgeons support a vertically oriented lift such as that achieved with an infraorbital approach, including subperiosteal and subfascial dissections.¹ Others have promoted a temporal midface-lift via a subperiosteal approach.² Another technique that is purported to offer superior midface and jawline correction is the deep-plane face-lift. Since the

*See also pages 191
and 193*

introduction of the deep-plane face-lift in 1990 by Hamra,³ much debate has ensued over the benefits of this technique. Many support this approach only anecdotally, noting a more natural refinement of the malar and jowl complexes. Critics portray this as a Pyrrhic victory, gained at too great a cost in the form of prolonged convalescence and potential nerve injury. Still others question altogether the claims of midface improvement.

Questions about the benefits of face-lift approaches are not new, yet there has been a scarcity of objective evidence to corroborate or refute these judgments. This may relate to the inadequacies inherent in judging face-lift results. Short of unwieldy 3-dimensional imaging systems, no practice-friendly device or method exists for reproducibly measuring real changes in soft tissue volume, although promising personal computer-based applications are on the horizon.⁴ Photogrammetric measures of the face are notoriously inaccurate.⁵ While commendable, previous comparisons of face-lift results have largely relied on subjective evaluation or on photographic criteria.⁶⁻⁹ In these studies, patients and experienced surgeons were unable to resolve significant differences in short-term outcomes between groups of patients undergoing more traditional vs more extensive face-lifts. In a split-treatment study¹⁰ comparing one hemiface with the other, neither the investigators nor the patients noted a perceptible advantage associated with the more extensive dissection. One might infer from such findings that the extended sub-superficial musculoaponeurotic sys-

Author Affiliations:
Department of
Otolaryngology–Head and Neck
Surgery, University of Toronto,
Toronto, Ontario.

tem (sub-SMAS) plication or deep-plane face-lift accomplishes nothing more than to increase operating time, complication risk, and surgeon apprehension.

This stands in stark contrast to the experiential account of those who routinely use the deep-plane face-lift approach, which is translatable into measurable advantages for the patient and the practice. Kamer and Frankel¹¹ noted a 3-fold reduction in tuck-up procedures on switching to the deep-plane approach. Our experience anecdotally substantiates this. However, the question remains as to what the deep-plane face-lift achieves, and how the change (if any) can be computed.

We sought to submit prevailing face-lift techniques to objective intraoperative testing using well-accepted anthropometric measurement tools. To eliminate confounding variables, we standardized the face-lift approaches so that the degree of SMAS manipulation remained the only dependent variable. Our discussion of the results draws some conclusions regarding the merits of the techniques used.

METHODS

All patients electing to undergo a deep-plane face-lift from December 1, 2004, to June 30, 2005, were eligible for inclusion in the study. One patient was excluded because of prior facial trauma and scarring. A consecutive sample of 32 patients participated, with a mean age of 55 years (age range, 41-65 years). There were 30 women and 2 men. Four of the procedures were secondary face-lifts, while the remaining 28 patients underwent primary face-lifts. The prior lifts were all SMAS manipulations. One patient underwent a revision of a previous procedure performed by us. Concurrent procedures included 16 forehead lifts, 10 upper and 13 lower blepharoplasties, 3 rhinoplasties, and 4 perioral laser resurfacing procedures. All other lift procedures were performed before the rhytidectomy procedure.

The patients were submitted sequentially to 3 progressively more extensive lifts on each hemiface, while all other lift variables were held constant (**Figure 1**). The procedures included SMAS plication, imbrication, and deep-plane face-lifts. Four major lift variables were studied. In the first group of 15 patients, the absolute amount of total lift was recorded on each side. This was ascertained by calculation of the skin excess without tension along the vector of pull overlying the mandibular line as measured from the cut skin edge to the intertragal incisural notch following each of the 3 lifts (**Figure 2**). In a second group of 17 patients, the degree of soft tissue repositioning was recorded in each of 3 specific areas of common interest, along the midface, jawline, and neck (**Figure 3**). For these measurements, arbitrary study points were marked on the skin before surgery at positions 4 cm inferior to the intertragal incisure, 4 cm anterior to the intertragal incisure along the jawline, and 2 cm inferolateral to the lateral canthus. We selected these points to correspond with each specific area of interest and to parallel the anticipated superolateral vector of pull in each of these subareas. The amount of lift was recorded by measuring the distance from these study points to accepted fixed anthropometric reference points, including the subnasale for the midface, the menton for the jawline, and the thyroid notch for the neck area. These lengths were chronicled at baseline and immediately after surgery for each of the 3 face-lifts in each hemiface using a standard spreading caliper (Paleo-Tech Concepts Inc, Crystal Lake, Ill) that is accurate to 0.5 mm with interpolation.

The degree of skin undermining constituted 3 cm anterior and posterior to the auricle and was not altered across each pro-

cedure. Lift fixation was standardized by maintenance of a stable vector of lift through placement of a single 3-0 polyglycolic acid suture in each subarea as follows: (1) from 1 cm below the mandibular margin to the mastoid fascia along a vector parallel to the jawline in the neck, (2) along a vector from the oral commissure to the root of the helix in the lower face, and (3) from the apex of the malar eminence to the temporal fascia at the hairline in the midface area. A maximal amount of suture tightening was carried out at each interval to obtain the greatest possible degree of lift in each procedure.

In the first procedure, a simple plication was carried out without excision of intervening SMAS fascia. This lift corresponds to what is now commonly referred to as the short flap face-lift. In the second procedure, a J-shaped portion of SMAS approximately 3 cm in width was excised extending from below the earlobe to the zygomatic arch, followed by imbrication of the SMAS fascia. This standard SMAS face-lift is the most commonly performed face-lift technique.¹² In the third procedure, a modified deep-plane dissection was performed beginning at the existing anterior cut edge of the SMAS. A sub-SMAS flap was developed and carried out over the malar surface as described by Hamra.³ The dissection of the neck was completed in a subplatysmal plane, a modification of the published technique. This allowed for creation of a single robust fasciocutaneous flap spanning from the zygoma to the neck. Medial margins of dissection were about 2 cm lateral to the melolabial fold and anterior to the jowl complex in the face and 3 cm inferior to the mandibular margin in the neck. An imbrication of the SMAS flap identical to the preceding lifts was then executed, and measurements were obtained. We routinely perform a midline platysmaplasty with plication of the anterior platysmal borders at the conclusion of the procedure so as not to impede the superolateral lift.

Statistical analysis was performed using SAS software (version 8, SAS Institute Inc, Cary, NC). Data were analyzed using repeated-measures analysis of covariance. Additional post hoc pairwise *t* tests were used to discern significant differences within groups. Interaction effects between tested variables were also ascertained.

RESULTS

The mean skin excesses were 10.4, 12.8, and 19.4 mm for the SMAS plication, imbrication, and deep-plane techniques, respectively (**Figure 4**). The mean extents of soft tissue repositioning in the neck were 7.1, 9.9, and 13.6 mm from baseline for each of the 3 lifts, respectively, and similar values obtained in the lower face were 7.9, 10.9, and 15.3 mm. Malar soft tissues achieved the least amount of soft tissue repositioning, where measures of 1.1, 2.0, and 4.0 mm were noted for each of the 3 techniques, respectively (**Figure 5**).

Analysis revealed significant differences from baseline and between lift types for each of the studied techniques in each of the variables tested ($P < .001$). Repeated-measures analysis of covariance was used to test whether the 3 slopes describing the relationship between the lift type (SMAS plication, imbrication, and deep plane) and the degree of repositioning were the same for all 3 areas tested (midface, jawline, and neck). This interaction was significant ($F_{4,132} = 4.8, P = .001$), indicating that the degree of repositioning was significantly greater across lift types in at least 1 area tested. Pairwise *t* tests were used to compare pairs of slopes to determine which slopes differed from the others. The results revealed that the slope for midface re-

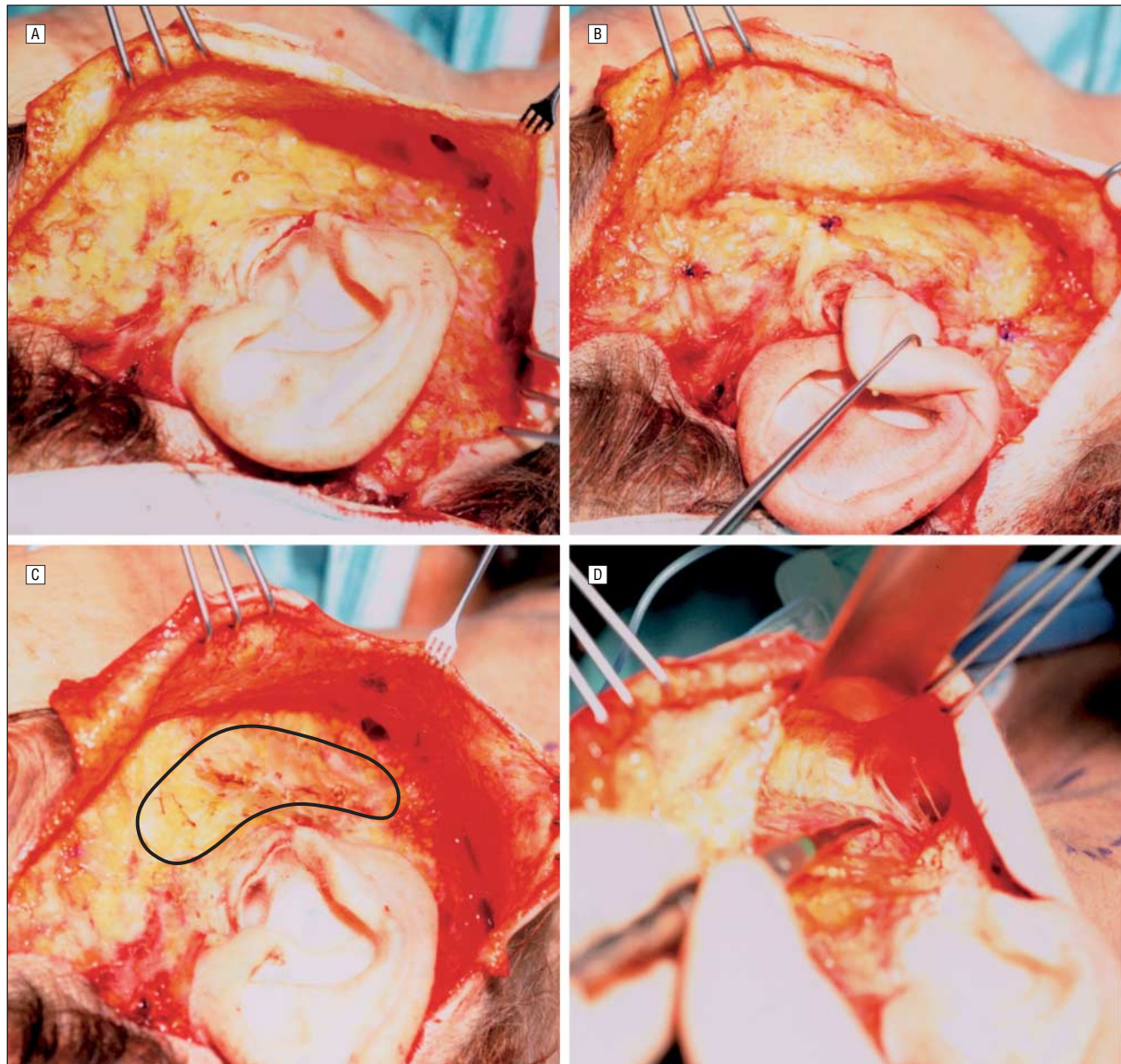


Figure 1. Intraoperative photographs of the limits of dissection. A, Extent of cutaneous undermining. B, Superficial musculoaponeurotic system (SMAS) plication, with sutures marked. C, Imbrication, with cut SMAS edges delineated by solid lines. D, Modified deep-plane face-lift dissection, with the pointer showing cervical branches of the facial nerve entering the platysma.

positioning was significantly different from the slopes for jawline repositioning ($t=-4.04$, $P<.001$) and neck repositioning ($t=-3.2$, $P=.002$), but the slopes for jawline and neck repositioning were not statistically different ($t=0.82$, $P=.41$). In other words, while the degree of midface improvement increased significantly among lift types, its overall lesser degree of improvement compared with the jawline and neck areas was statistically confirmed.

Extensive lifts in the neck or lower face almost invariably achieved good repositioning of the midfacial soft tissues. Some patients with more elastic tissues obtained lifts of as much as 8 mm in the midface and 31 mm in the lower face and neck, while at the opposite end of the spectrum a few patients with exceedingly inelastic tissues achieved lifts of as little as 1 mm in the midface and 6 mm in the lower face. One such patient was

undergoing a revision procedure. These outlying extremes were rare, however, with most patients falling within a narrow range of values. As might be expected, the improvements among men and among patients undergoing revisions were somewhat less than average. Some patients undergoing revision procedures who obtained suboptimal corrections in the lower face and neck still achieved average improvement of midfacial ptosis. There was no patient for whom a more extensive lift did not achieve a greater improvement.

COMMENT

This study exposed robust distinctions between the SMAS plication, imbrication, and deep-plane face-lift techniques for the degree of lift attained within each subarea

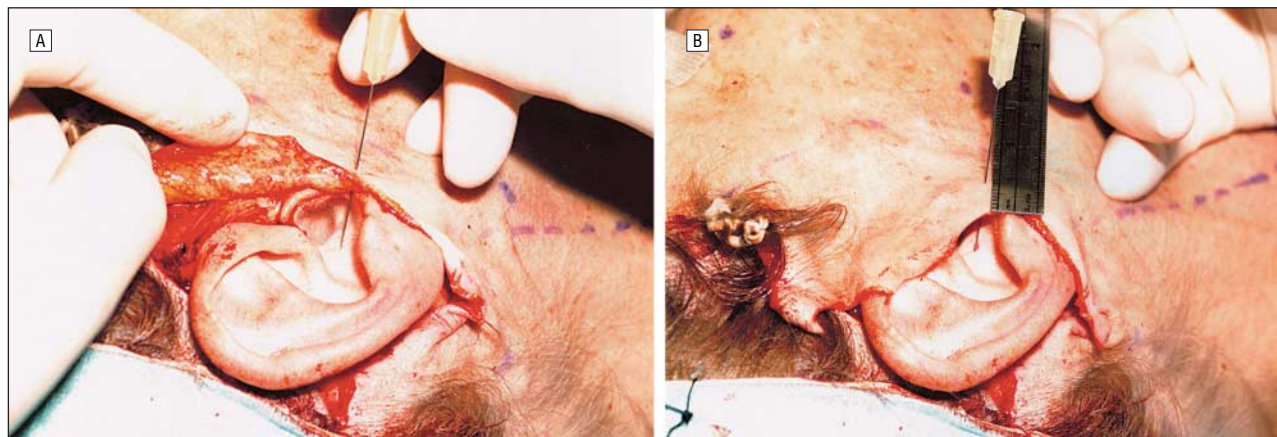


Figure 2. Intraoperative photographs demonstrating the calculation of skin excess along a vector parallel to the mandibular line. A, Identification of a point overlying the intertragal incisure. B, Measurement using a standard ruler from the identified point to the cut skin edge.

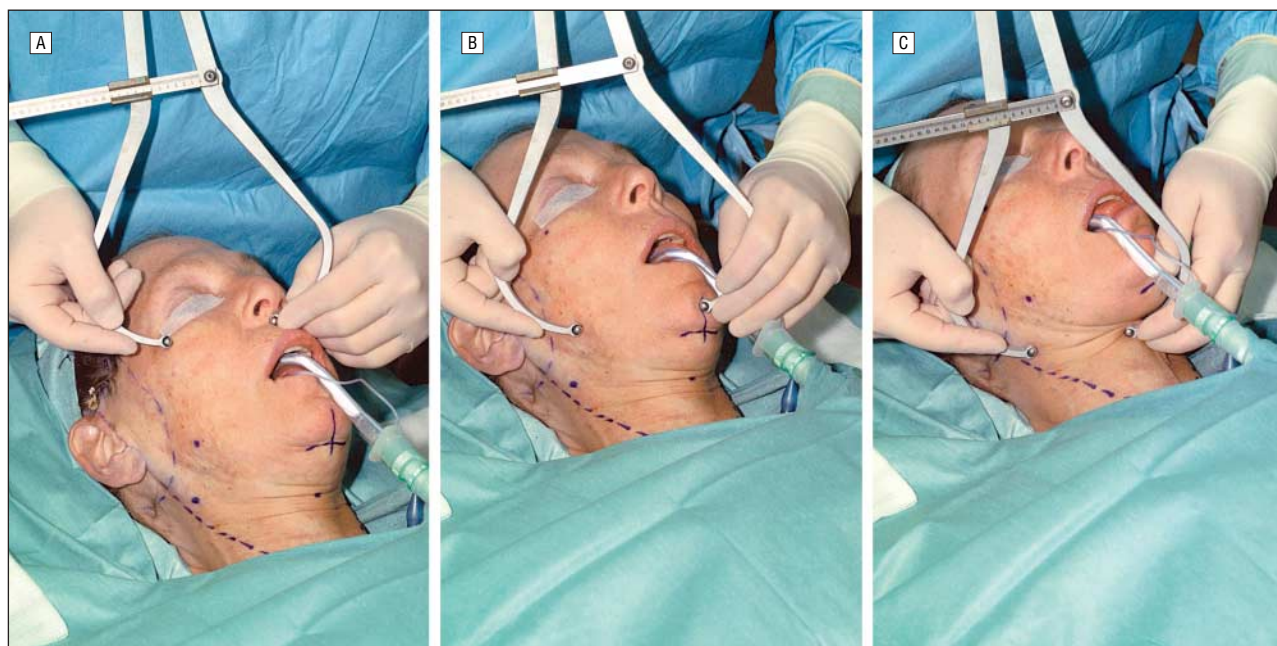


Figure 3. Calculation of soft tissue repositioning achieved, measuring from standardized study points to fixed anthropometric midline reference points in the midface (A), jawline (B), and neck (C).

of the aging lower face. Almost double the lift was achieved using the deep-plane technique compared with the short flap lift. Although minimally invasive techniques occupy center stage in the public eye, our data present compelling evidence to promote a more aggressive tack. Our study is not without limitations, however. The arbitrary method of testing used was perhaps a necessary evil, as no accepted standard exists for the objective measurement of face-lift procedures in the aging face. The points or vectors chosen may have overexposed or underexposed real or imaginary differences in the intraoperative outcomes. However, further fortification of our 3 arguably paltry sutures might have likely disclosed an even more vigorous disparity. More expansive flap suspension might accentuate the results demonstrable with the more widely undermined deep-plane flap.

What can be made of the sticky question of purported midface enhancements using the deep-plane tech-

nique? Surgeons who oppose extensive face-lifts will point to the more conservative midfacial soft tissue repositioning as evidence of a lack of clinical utility, despite the statistical significance of our results herein. These measures should not be disparaged. The human eye is capable of almost submillimetric discrimination between features.¹³ Surgeons exploit this attribute to achieve natural enhancements via subtle changes.

The chief limitation of this study lies in the inability to reproduce such measures to establish the long-term stability of the lifts achieved. Even the originator of the technique¹⁴ has questioned the long-term benefits of the deep-plane face-lift for midface enhancements. Our data serve to elucidate these conclusions, notwithstanding the intrinsic weaknesses of past inferences derived from photogrammetric evaluations. In absolute terms, the slightest improvements were achieved in the midface. Erosion of the face-lift improvements by parallel aging of all

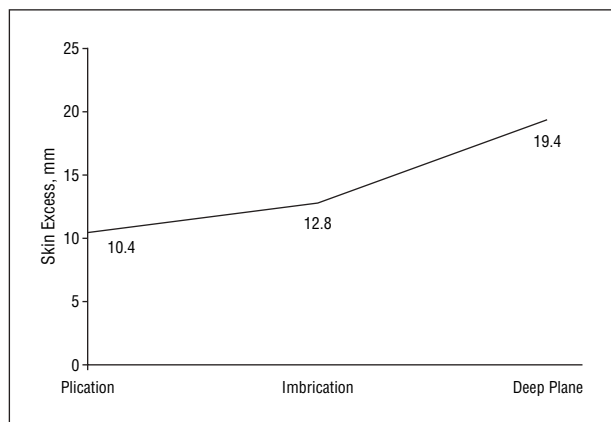


Figure 4. Graph showing the differences in mean skin excess obtained with superficial musculoaponeurotic system plication, imbrication, and deep-plane face-lift techniques.

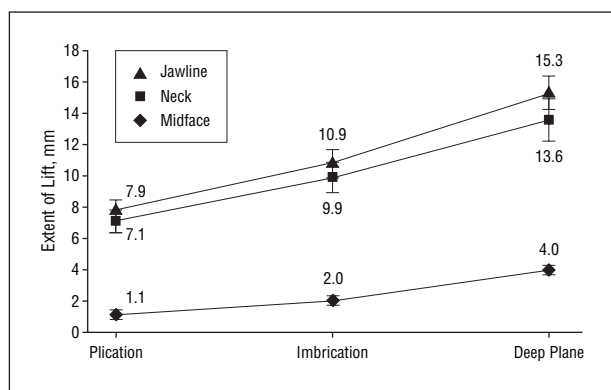


Figure 5. Graph showing the extent of soft tissue repositioning achieved across the 3 lift types in the jawline, neck, and midface.

facial subunits might manifest more readily in the midface. In other words, the midfacial tissues do not have as far to fall in the years following a deep-plane face-lift. In relative terms, on the other hand, the midface was proportionately the greatest beneficiary in our study, with more than double the repositioning achieved compared with the lesser lifts. Intuition suggests that these proportionate changes, however small, should be maintained with passage of time, thereby preserving the relative superiority of the deep-plane technique over its less invasive counterparts. Although something must be said for clinical experience and instinct, the lasting effects of a technique cannot be fully endorsed by intuition alone. Further answers to this worthy question will perhaps be borne out with time and improved study techniques.

CONCLUSIONS

The ultimate driver of our specialty, more than any other, is patient satisfaction. Rhytidectomy of any kind has long been associated with a high level of patient approval ratings, which necessitates population surveys of such a large scale so as to render them nearly impossible. Many sur-

geons are understandably discouraged from initiating questionably more perilous techniques such as the deep-plane face-lift to improve on what is already considered a reliable operation. The recent resurgence of minimally invasive techniques is a testament to our need to answer to other patient demands such as negligible risk and minimal downtime. On the other hand, a technique's capacity to provide an unquestionably greater improvement of questionably enduring longevity can weigh heavily in a patient's decision-making process. As with any study, deductions drawn from our data fall within the realm of interpretative experience. Some will conclude that results of more extensive face-lifts do not merit the added risk. Although this study provides only a small piece of a puzzle, we believe that these intraoperative findings support our continuing experience of a natural and lasting panfacial enhancement achieved using our modified deep-plane face-lift technique.

Accepted for Publication: January 25, 2006.

Correspondence: Peter A. Adamson, MD, FRCSC, FACS, Department of Otolaryngology–Head and Neck Surgery, University of Toronto, Renaissance Plaza, Suite M110, 150 Bloor St W, Toronto, Ontario, Canada M5S 2X9 (paa@dradamson.com).

Acknowledgment: We thank Laurel Duquette, PhD, for her statistical analysis of this work.

REFERENCES

- Freeman MS. Transconjunctival sub-orbicularis oculi fat (SOOF) pad lift blepharoplasty: a new technique for the effacement of nasojugal deformity. *Arch Facial Plast Surg.* 2000;2:16-21.
- Williams EF III, Vargas H, Dahiya R, Hove CR, Rodgers BJ, Lam SM. Midfacial rejuvenation via a minimal-incision brow-lift approach: critical evaluation of a 5-year experience. *Arch Facial Plast Surg.* 2003;5:470-478.
- Hamra ST. The deep-plane rhytidectomy. *Plast Reconstr Surg.* 1990;86:53-61.
- Honrado CP, Larrabee WF Jr. Update in three-dimensional imaging in facial plastic surgery. *Curr Opin Otolaryngol Head Neck Surg.* 2004;12:327-331.
- Farkas LG, Bryson W, Klotz J. Is photogrammetry of the face reliable? *Plast Reconstr Surg.* 1980;66:346-355.
- Becker FF, Bassichis BA. Deep-plane face-lift vs superficial musculoaponeurotic system plication face-lift: a comparative study. *Arch Facial Plast Surg.* 2004; 6:8-13.
- Tipton JB. Should the subcutaneous tissue be plicated in a face lift? *Plast Reconstr Surg.* 1974;54:1-5.
- Rees TD, Aston SJ. A clinical evaluation of the results of submusculoaponeurotic dissection and fixation in face lifts. *Plast Reconstr Surg.* 1977;60:851-859.
- Webster RC, Smith RC, Papsidero MJ, Karolow WW, Smith KF. Comparison of SMAS plication with SMAS imbrication in face lifting. *Laryngoscope.* 1982; 92:901-912.
- Ivy EJ, Lorenc ZP, Aston SJ. Is there a difference? a prospective study comparing lateral and standard SMAS face lifts with extended SMAS and composite rhytidectomies. *Plast Reconstr Surg.* 1996;98:1135-1143.
- Kamer FM, Frankel AS. SMAS rhytidectomy versus deep plane rhytidectomy: an objective comparison. *Plast Reconstr Surg.* 1998;102:878-881.
- Matarasso A, Elkwood A, Rankin M, Elkowitz M. National plastic surgery survey: face lift techniques and complications. *Plast Reconstr Surg.* 2000;106:1185-1196.
- Etcoff N. *Survival of the Prettiest: The Science of Beauty.* New York, NY: Anchor; 2000.
- Hamra ST. A study of the long-term effect of malar fat repositioning in face lift surgery: short-term success but long-term failure. *Plast Reconstr Surg.* 2002; 110:940-951.